

Antimicrobial agents: Case approach

Porntep Suandork M.D.

Pediatric Infectious Disease Specialist

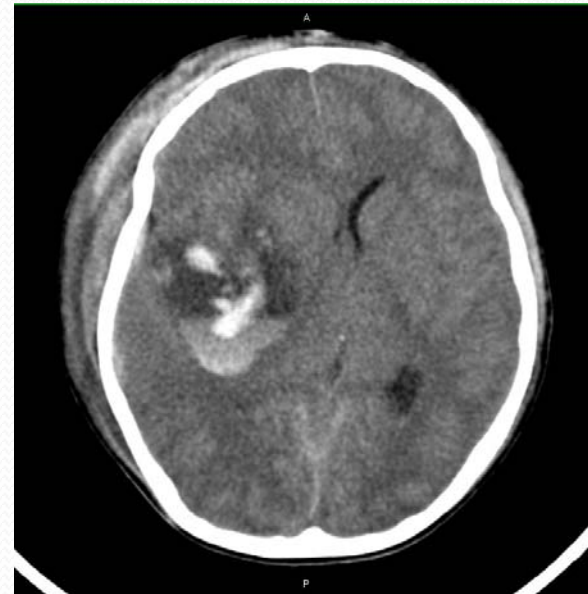
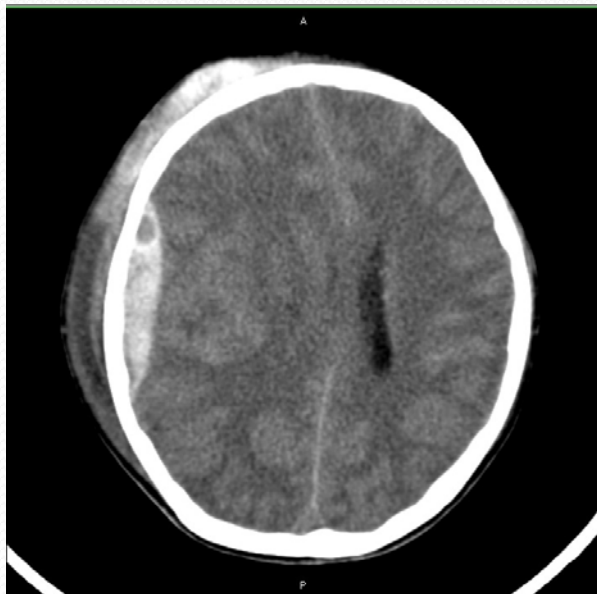Bangkok Hospital

เด็กชายไทยอายุ 12 ปี จ.ปราจีนบุรี

- Refer จากกรพ.จังหวัดด้วยเรื่อง brain injury
- Motorcycle accident with severe brain injury
- Bleeding from right ear with fracture right orbit
- E1M4VT
- Neck: limit ROM on collar support

CT brain

- Epidural hematoma at right temporal and parietal area
- Small hemorrhage in midbrain
- Diffuse brain edema with minimal herniation to left
- Fracture of lateral wall right orbit and maxillary sinus



Hospital course (รพ.จังหวัด)

- Intubation
- Dexamethasone IV
- Omeprazole IV
- Dilantin IV
- ญาติขอ refer มารพ.กรุงเทพ

Hospital course (รพ.กรุงเทพ)

- Intubation with ventilator, central line x II, urethral catheter, NG tube
- Craniotomy with clot removal, on ICP monitoring
- Ceftriaxone 2 g IV q 12 h