


Fever with Sore Throat

Case Approach



Discussed by Kriengsak Limkittikul
Porntep Suandork
Thition Narkbunnam
Moderated by Chitsanu Pancharoen

Content

Fever with sore throat

Oral ulcers

Pharyngotonsillar lesions

Design

Case discussion

Mini-lecture

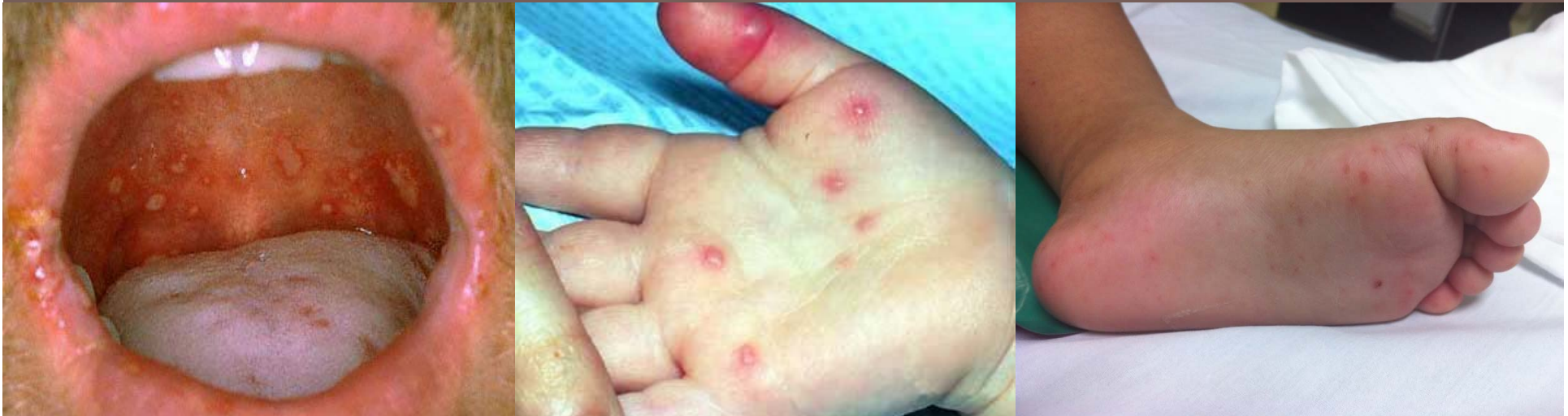Lesson learnt and conclusion

CASE 1: 5-yr-old boy

Oral Ulcers

Hx: fever, drooling

PE: multiple vesicles in oral cavities
papulovesicular lesions on palms and soles



CBC: Hct 37%, wbc 12,000/mm³ (N 50%,
L 45%, Mo 5%), platelet 150,000 mm³

CASE 1: 5-yr-old boy

Oral Ulcers

Q1: DDX

- A. Hand-foot-mouth disease (HFMD)
- B. Herpetic gingivostomatitis
- C. Herpangina
- D. Kawasaki disease

CASE 1: 5-yr-old boy

Oral Ulcers

Q2: Investigation

- A. Viral study: EV71, coxsackie, herpes
(specimens – lesions, NP suction, stool)
- B. Tzanck smear
- C. Echocardiogram